

Conventional videodefecography: pathologic findings regarding gender and age - our experience

Poster No.: C-1468
Congress: ECR 2012
Type: Scientific Exhibit
Authors: L. Andrade¹, H. Nunes Correia², C. Antunes¹, L. Curvo-Semedo¹, B. Graça¹, J. Ilharco¹, F. Caseiro Alves¹; ¹Coimbra/PT, ²Viseu/PT
Keywords: Pelvic floor dysfunction, Defecography, Fluoroscopy, Conventional radiography, Gastrointestinal tract
DOI: 10.1594/ecr2012/C-1468

Any information contained in this pdf file is automatically generated from digital material submitted to EPOS by third parties in the form of scientific presentations. References to any names, marks, products, or services of third parties or hypertext links to third-party sites or information are provided solely as a convenience to you and do not in any way constitute or imply ECR's endorsement, sponsorship or recommendation of the third party, information, product or service. ECR is not responsible for the content of these pages and does not make any representations regarding the content or accuracy of material in this file.

As per copyright regulations, any unauthorised use of the material or parts thereof as well as commercial reproduction or multiple distribution by any traditional or electronically based reproduction/publication method is strictly prohibited.

You agree to defend, indemnify, and hold ECR harmless from and against any and all claims, damages, costs, and expenses, including attorneys' fees, arising from or related to your use of these pages.

Please note: Links to movies, ppt slideshows and any other multimedia files are not available in the pdf version of presentations.

www.myESR.org

Purpose

- Radiographic dynamic rectal examination (defecography) is a valuable method to assess evacuation disorders.
- The most common indications are constipation, incomplete evacuation or incontinence and perineal pain.
- Evacuation disorders, frequently found in elderly patients, are often caused by morphologic and functional abnormalities due to changes in the musculoaponeurotic support of the pelvic floor, that are unlikely to be identified with static imaging techniques.
- Defecography evaluates in real time the morphology of rectum and anal canal in correlation with pelvic bony components both statically and dynamically.
- Posterior pelvic floor disorders are common and well known in women, and some are related to obstetrical consequences. Little is known about gender influence in symptomatic patients investigated by defecography.
- The purpose of our study was to review the most common disorders depicted with conventional videodefecography and compare the defecographic abnormalities between symptomatic patients regarding gender and age.

Methods and Materials

Patients

- 300 symptomatic patients (obstipation or incontinence) have undergone conventional videodefecography between January 2009 and August 2011 (32 months) at Coimbra University Hospitals
- Patients were addressed to conventional videodefecography on the basis of clinical evidence of evacuation disorders.
- 10 patients were excluded of our retrospective images analysis because of lack of evacuation.
- Gender and age distribution was: 266 females, 24 males; 15-87 year-old (mean: 57,7).

Defecography

- In our hospital we applied a standardized protocol to perform and evaluate all defecography examinations.
- 200-300 mL of barium paste was injected in the rectum by means of a plastic syringe connected to a catheter with the patient in the left lateral position.
- Barium paste is obtained by mixing equal proportions of potato starch and barium solution with water and must have the consistency of normal stool.
- Films were taken with patients sat in a lateral position (on a special commode with two or three water-filled annular pillows) during the following maneuvers: at rest, at voluntary and maximal contraction of the sphincter and pelvic floor ("squeeze") and at straining without defecation ("strain").
- Finally one frame per second films were taken during expulsion and after completion of defecation at rest.
- All patients were instructed to empty the rectum completely and without interruption: this process takes less than 30 seconds in physiologic conditions.
- Image analysis was done by one of the senior radiologists involved in this study.

Images interpretation [figure1]

- The anorectal angle (ARA) was measured between the anal canal longitudinal axis and the posterior rectal line, parallel to the longitudinal axis of the rectum. In resting conditions, its average value is 95° - 96° (physiological range, 65° - 100°); during muscle contraction, the angle becomes more acute, while during relaxing phase it becomes obtuse. ARA is an indirect indicator of the puborectal muscle activity.
- Pubococcygeal line (PCL) was drawn from inferior pubis to the last coccygeal joint.
- The distance from the pubococcygeal line to the anorectal junction (ARJ) was measured on images obtained when the patient was at rest and at maximal pelvic strain, to assess the position of the pelvic floor. The craniocaudal migration of anorectal junction indirectly represents the elevation and descent of pelvic floor.

- For the diagnosis of perineal descent at rest, the distance in centimeters between the ARJ and the PCL was noted. Perineal descent at rest was defined as a distance of > 6 cm. For perineal descent at straining, the difference in centimeters between the ARJ position at straining and at rest was noted. Perineal descent at straining was defined as a difference of $\geq 3,5$ cm between the two positions.
- Anterior rectocele was defined as an outpouching of the anterior rectal wall that persisted on incomplete evacuation. Radiopaque paste can be retained inside the pouch and persists at the end of defecation. Outpouchings smaller than 2 cm are frequently found in asymptomatic patients and are without clinical significance. We considered three degrees of rectocele: first degree is <2 cm in anteroposterior diameter (not clinically significant); second degree is between 2 and 4 cm; and third degree is ≥ 4 cm.
- Intussusception was defined as an invagination of the rectal wall, either intrarectal or intra-anal.
- An invagination of the whole circumference of the rectal wall was defined as external rectal prolapse.

Statistical analysis

- χ^2 tests were used for the comparison of rectocele, perineal descent, dyskinetic puborectalis muscle syndrome and intussusception.
- $P < 0.05$ was regarded as significant.

Images for this section:

Materials and Methods

Images interpretation

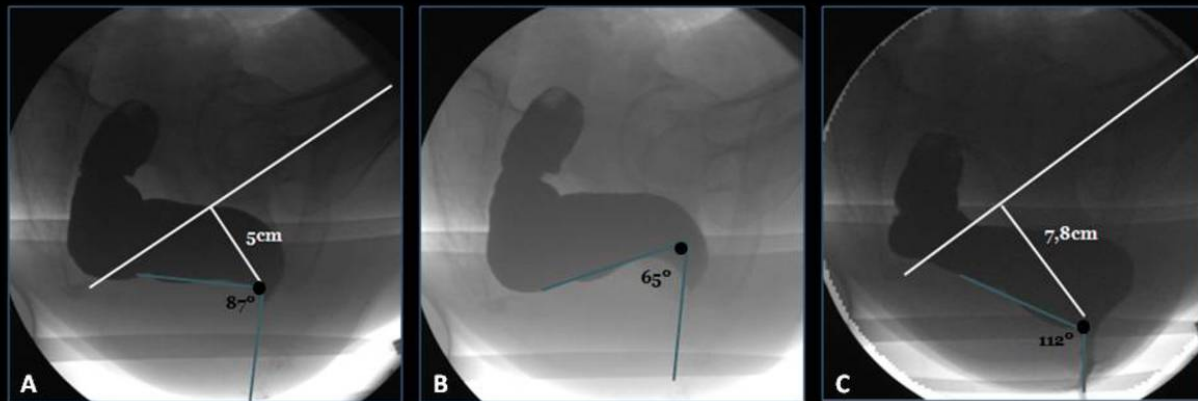


Fig.1: Normal defecography phases. At rest (A). During forced contraction (B). During defecation (C). Measurement of the ARA with the patient at rest (A), during maximal contraction (B), and during evacuation (C) (*blue lines*). The ARA decreases during maximal contraction of the anal sphincter and increases during evacuation, followed by descent of the ARJ (*black point at the intersection of the two lines defining the ARA*). The descent of the ARJ between resting position and evacuation is less than 3,5 cm in normal conditions.

Fig. 1: Normal defecographic findings

Results

- Of 290 patients 8% were male and 92% female.
- The average age was 57.7 (15-87) years.
- Constipation were the most frequent referral diagnosis.
- No abnormalities were found in 8,3% (24) symptomatic patients.
- Conventional defecography detected abnormalities of normal rectal voiding in 266 patients [Fig 2 and 3]: anterior rectocele (165 cases) [fig 4], intussusception (96 cases) [fig 5], external rectal prolapse (12 cases) [fig 5], dyskinetic puborectalis muscle syndrome (34 cases) [fig 6], descending perineum syndrome (119 cases) [fig 7], incontinence (28 cases).
- 165 patients were diagnosed with rectocele (125 [43,1%] had a 2nd degree rectocele and 40 [13,8%] a 3rd degree). None man had a rectocele clinically significant. This pathology is most commonly found in females because of laxity of the rectovaginal septum (congenital or caused by obstetrical traumas or surgical procedures).
- In complete external rectal prolapse all layers of the rectal wall invaginate and pass through the anus and prolapse externally. At defecography dilation of the anal canal is evident during evacuation. Most patients with external rectal prolapse have associated incontinence ($p=0.03$; OR: 7.9) [fig 8]. Evacuation can also be blocked by the intrarectal prolapsed wall which creates a plug obstructing the stool transit, causing barium paste to stagnate inside the viscus.
- In women the most frequent pathological findings were rectocele (62%), descending perineum syndrome (42,8%), intussusceptions (33,8%), incontinence (10,5%), dyskinetic puborectalis syndrome (9,4%) and rectal prolapse (4,5%); in men was the dyskinetic puborectalis syndrome (37,5%).
- Dyskinetic puborectalis syndrome is more likely in men than women ($p=0,01$; OR:5,78) [fig 9].
- Descending perineum syndrome ($p=0,027$; OR 2,8) is more likely to occur in women [fig 10]. This syndrome represents a condition of pelvic floor muscle hypotonia and is usually found in elderly women because the main risk factors are perineal trauma, multiparity, and surgical procedures
- In women with perineal descent, those younger than 50 years frequently present increased descent during evacuation (81,8%), while those older than 50 years already have a pelvic floor in low position during rest (60,3%)

($p < 0,001$; OR 6,8), with little change in evacuation [fig11]. The result suggests that fixed perineal descent may be a consequence associated with aging. In younger women the position of the pelvic floor is higher at rest with greater descent on evacuation, whereas the converse applies in the elderly with more descent at rest and less change on evacuation.

Images for this section:

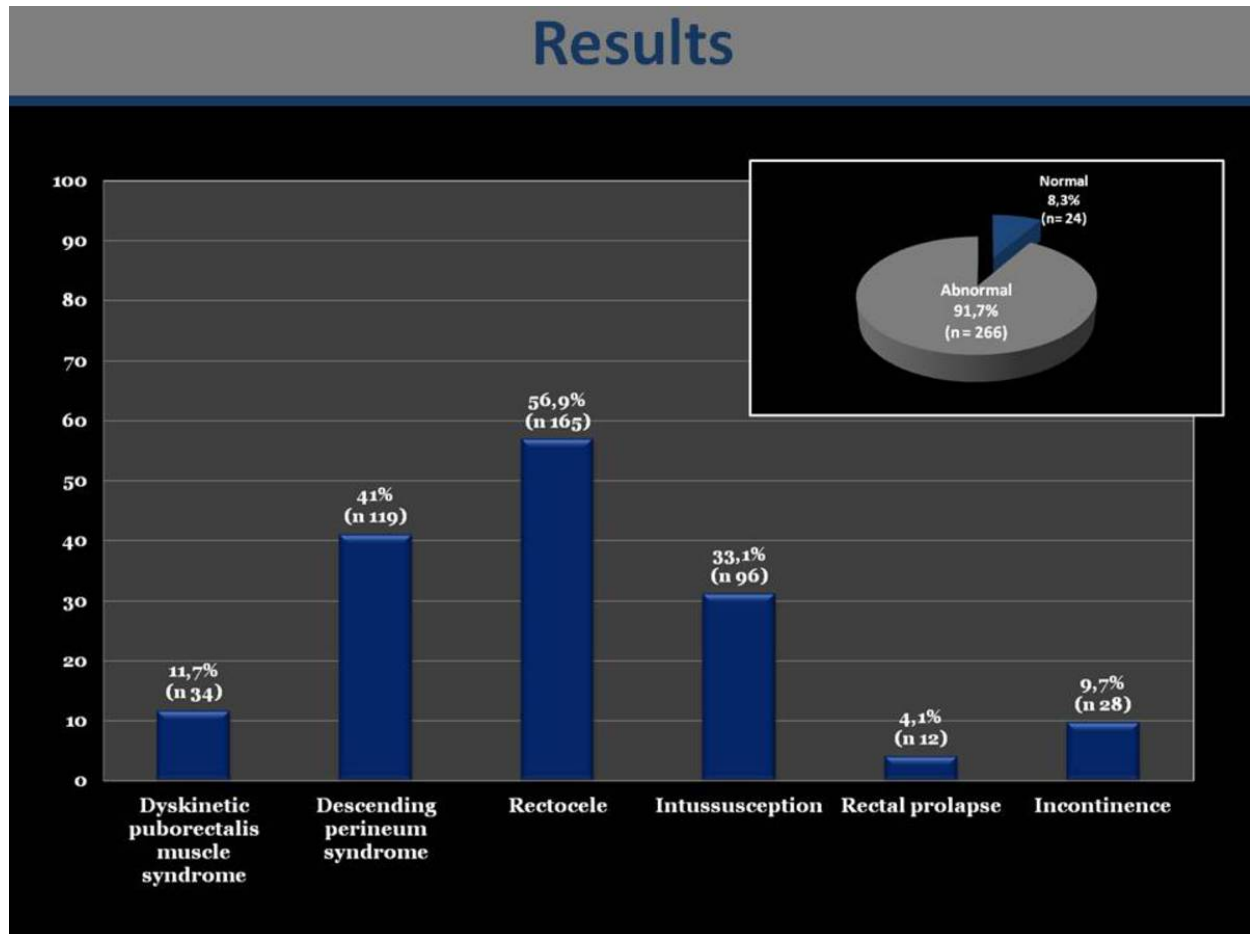


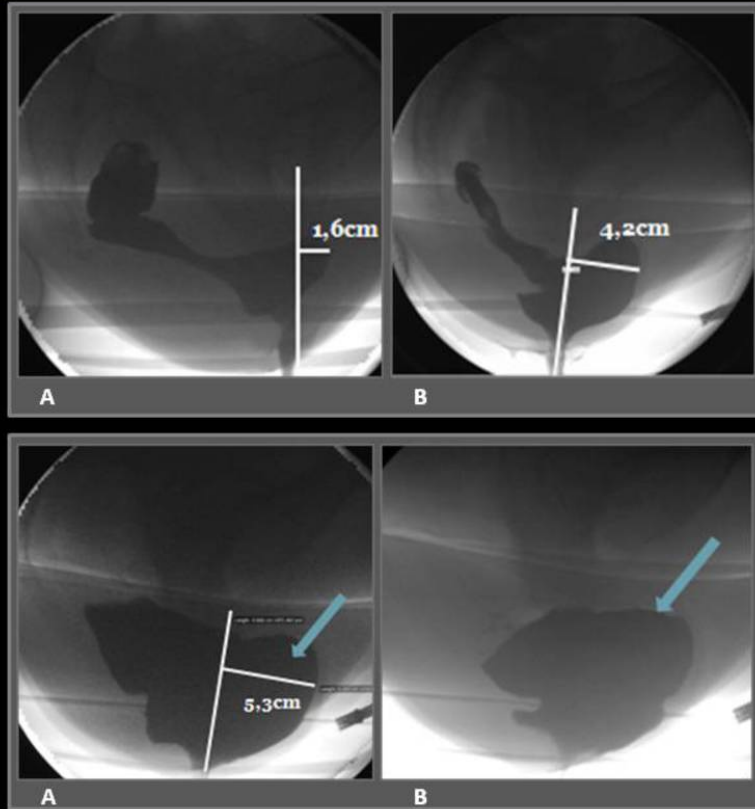
Fig. 2: Distribution of defecographic findings

Results

	Female (n= 266)	Male (n= 24)	Total (n= 290)
Normal defecography findings	20 (7,5%)	4 (16,7%)	24 (8,3%)
Rectocele			
1 st degree (< 2cm)	101 (38%)	24 (100%)	125 (43,1%)
2 nd degree (2-4cm)	125 (47%)	0	125 (43,1%)
3 rd degree (≥ 4cm)	40 (15%)	0	40 (13,8%)
Intussusception	90 (33,8%)	6 (25%)	96 (33,1%)
Rectal prolapse	12 (4,5%)	0	12 (4,1%)
Dyskinetic puborectalis syndrome	25 (9,4%)	9 (37,5%)	34 (11,7%)
Descending perineum syndrome			
At rest	53 (19,9%)	1 (4,2%)	54 (18,6%)
With strain / during evacuation	58 (21,8%)	4 (16,7%)	62 (21,4%)
Both	3 (1,1%)	0	3 (1%)
Incontinence	28 (10,5%)	0	28 (9,7%)

Fig. 3: Distribution of defecographic findings regarding gender

Results



Outpouchings smaller than 2 cm are without clinical significance and not considered pathological (1st degree) (A).
Third degree rectocele (B).

43 yo woman with obstipation; the patient needed manual assistance (vaginal digitations) to empty the rectum. Videodefecography shows a large anterior rectocele (3rd degree) (A). During defecation the rectocele was filled with barium paste and she was unable to empty the rectum, even during maximal effort so the contrast persisted at the end of defecation (B).

Fig. 4: Rectocele

Results

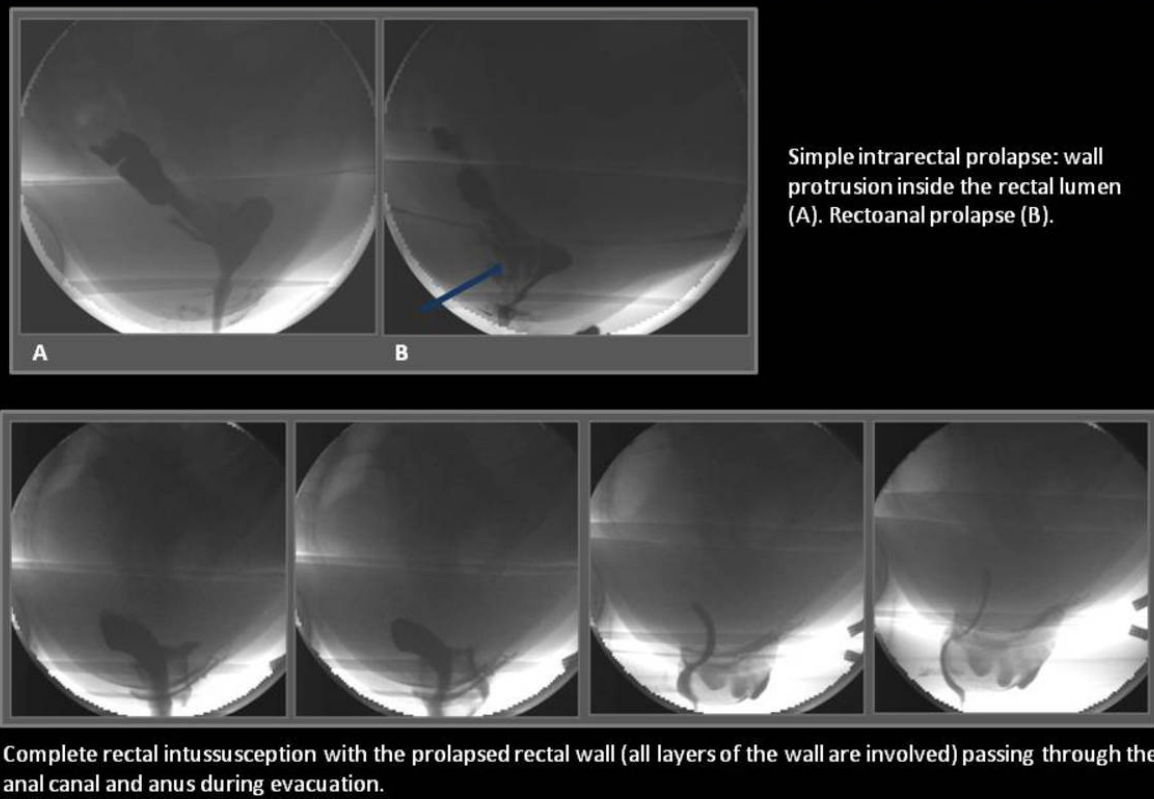
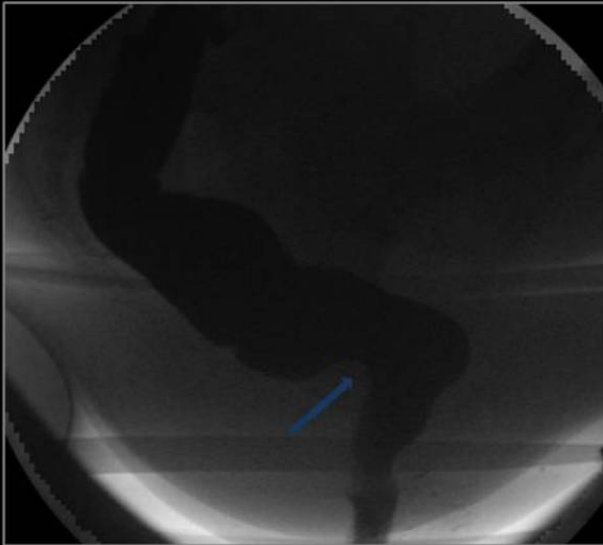


Fig. 5: Intussusception and external rectal prolapse

Results

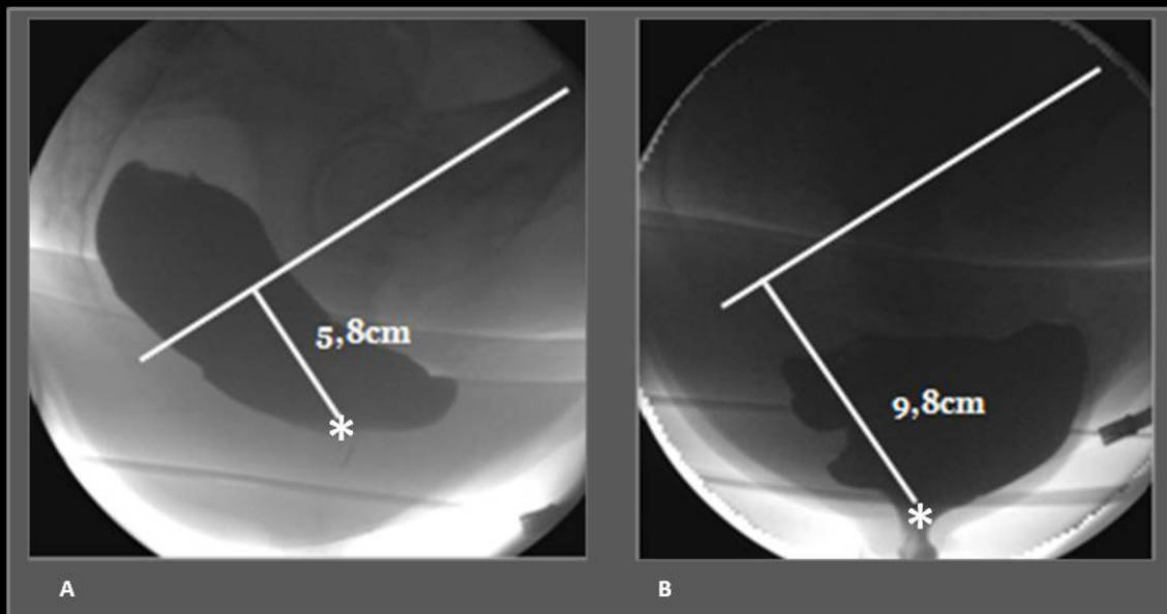


Spastic pelvic floor syndrome in a 38 year-old man. Defecography obtained with the patient at rest shows normal findings (*not shown*). Defecograms obtained during straining and attempted defecation show paradoxical contraction of the puborectal (*arrow*) - at strain ARA paradoxically closes and anal sphincter fails to open, for inappropriate contraction of puborectalis muscle, which conforms to spastic pelvic floor syndrome.

The diagnosis was confirmed with electromyography.

Fig. 6: Dyskinetic puborectalis syndrome

Results



Descending perineum syndrome. Note the descent of the anorectal junction (*asterisk*) between resting position (A) and during evacuation (B). PCL is considered as the reference level. A large rectocele is also evident.

Fig. 7: Descending perineum syndrome

Results

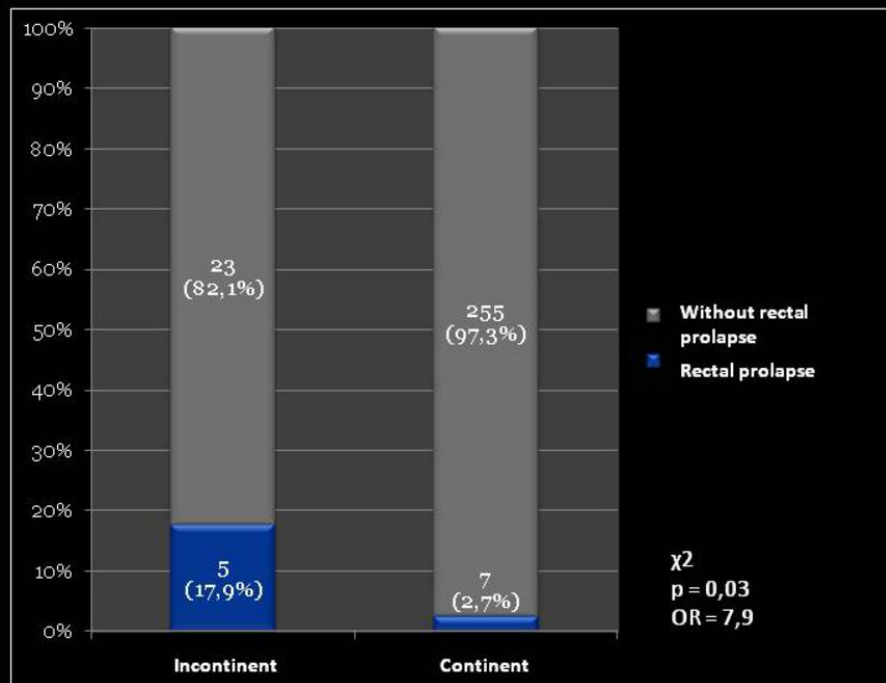


Fig. 8: Incontinence and rectal prolapse association

Results

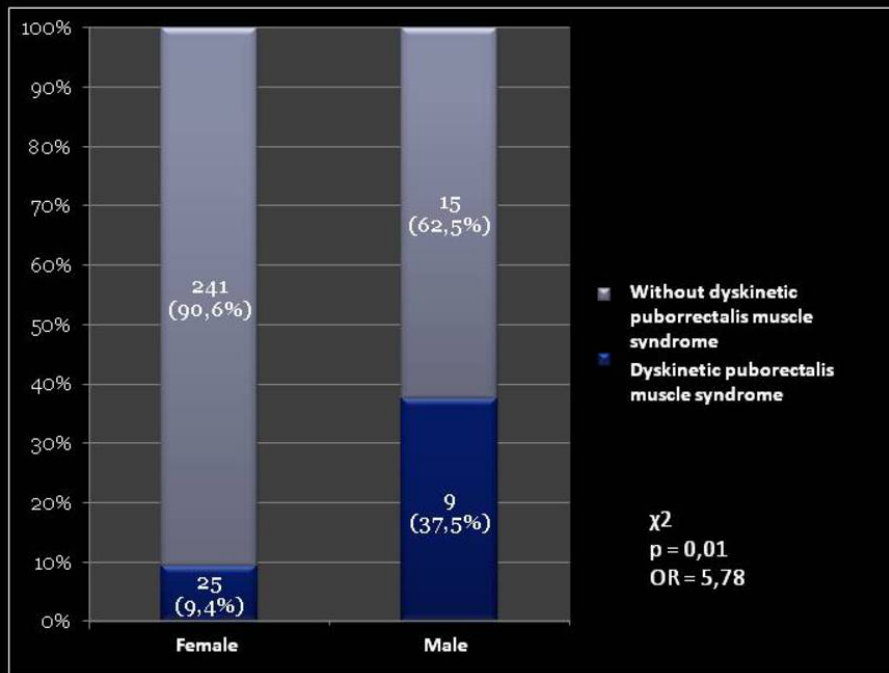


Fig. 9: Dyskinetic puborectalis muscle syndrome regarding gender

Results

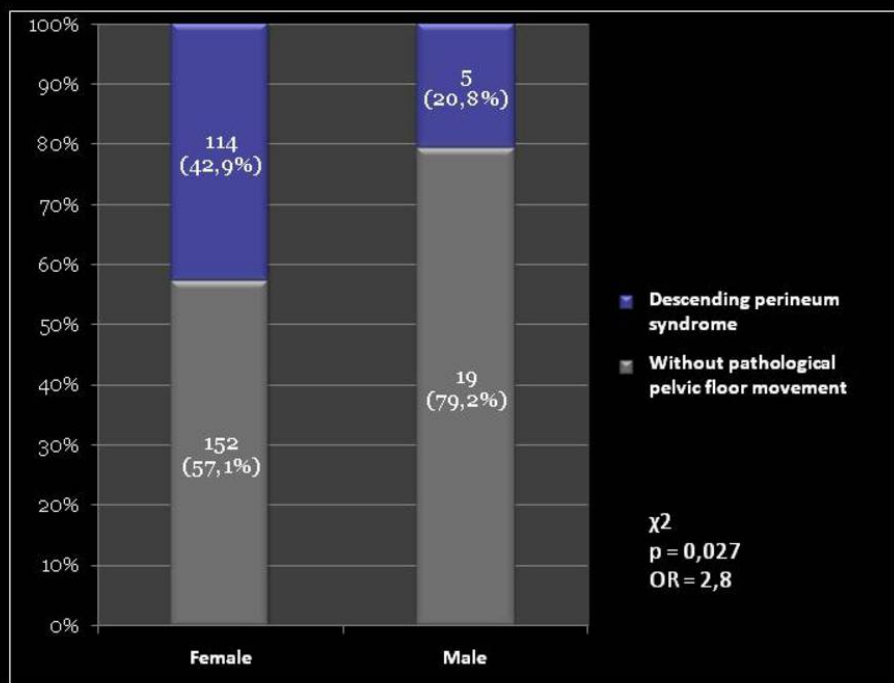


Fig. 10: Descending perineum syndrome regarding gender

Results

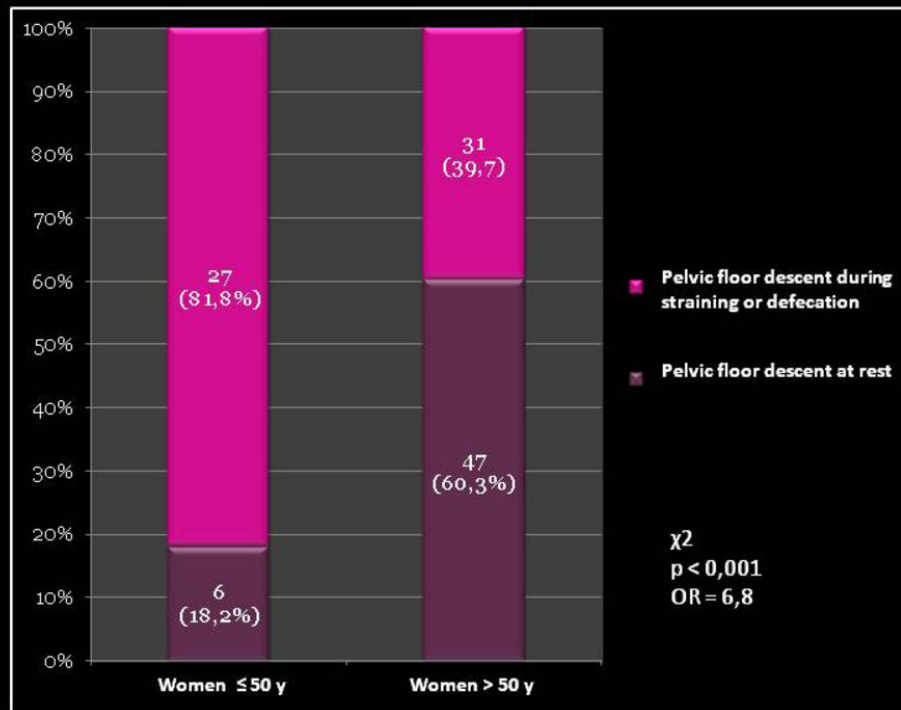


Fig. 11: Descending perineum syndrome regarding women age

Conclusion

- Videodefecographic findings varies with age and gender.
- Men are more likely to have the dyskinetic puborectalis syndrome.
- Descending perineum syndrome is more probable in women.
- With increasing age women tend to have a lower pelvic floor position, even at rest.
- Conventional videodefecography remains a valuable exam in the identification of morphological and functional changes related to evacuation.

References

Faccioli N, Comai A, Mainardi P, Perandini S, Moore F, Pozzi-Mucelli R. Defecography: a practical approach. *Diagn Interv Radiol*. 2010 Sep;16(3):209-16.

Ganeshan A, Anderson EM, Upponi S, et al. Imaging of obstructed defecation. *Clin Radiol* 2008; 63:18-26.

Goei R, van Engelshoven J, Schouten H, Baeten C, Stassen C. Anorectal function: defecographic measurement in asymptomatic subjects. *Radiology* 1989;173(1):137-41.

Karasick S, Karasick D, Karasick SR. Functional disorders of the anus and rectum: findings on defecography. *AJR Am J Roentgenol* 1993; 160:777-782.

Maglinte DD, Bartram C. Dynamic imaging of posterior compartment pelvic floor dysfunction by evacuation proctography: techniques, indications, results and limitations. *Eur J Radiol* 2007;61(3):454-61.

Pomerri F, Zuliani M, Mazza C, Villarejo F, Scopece A. Defecographic measurements of rectal intussusception and prolapse in patients and in asymptomatic subjects. *AJR Am J Roentgenol* 2001;176(3):641-5.

Savoye-Collet C, Koning E, Dacher JN. Radiologic evaluation of pelvic floor disorders. *Gastroenterol Clin North Am* 2008; 37: 553-567, viii

Savoye-Collet C, Savoye G, Koning E, Leroi AM, Dacher JN. Gender influence on defecographic abnormalities in patients with posterior pelvic floor disorders. *World J Gastroenterol*. 2010 Jan 28;16(4):462-6.

Shorvon PJ, McHugh S, Diamant NE, Somers S, Stevenson GW. Defecography in normal volunteers: results and implications. *Gut* 1989;30(12):1737-49.

Touchais JY, Koning E, Savoye-Collet C, Leroi AM, Denis P. [Role of defecography in female posterior pelvic floor abnormalities] *Gynecol Obstet Fertil* 2007; 35: 1257-1263

Personal Information

Luísa Andrade (isa.c.andrade@hotmail.com);

Radiology Department, Coimbra University Hospital, Coimbra,
Portugal